

ARTICLE

A case of tetrophthalmia with unilateral synophthalmia in an unborn fetus of blue shark *Prionace glauca* (Carcharhiniformes, Carcharhinidae)

Un caso de tetroftalmia con sinoftalmia unilateral en un feto nonato de tiburón azul *Prionace glauca* (Carcharhiniformes, Carcharhinidae)

Víctor Pastén-Marambio¹, Valentina Hevia-Hormazábal¹,
Enzo Acuña^{1,2*} and J.M. Alonso Vega¹

¹Departamento de Biología Marina, Facultad de Ciencias del Mar, Universidad Católica del Norte, Casilla 117, Coquimbo, Chile. *eacuna@ucn.cl

²Millenium Nucleus for Ecology and Sustainable Management of Oceanic Islands (ESMOI), Departamento de Biología Marina, Universidad Católica del Norte, Coquimbo, Chile

Resumen.- Este estudio describe y clasifica un caso de malformaciones múltiples en un feto nonato de tiburón azul *Prionace glauca*, extraído de una hembra grávida capturada durante una campaña de investigación biológica de tiburones en el norte y centro de Chile. El espécimen analizado presenta tetroftalmia con sinoftalmia unilateral, anomalía caracterizada por la existencia de 4 globos oculares, dos de los cuales están parcialmente fusionados. Además, el esqueleto axial del feto muestra lordosis torácica y torsión helicoidal en la porción abdómino-caudal. Este es el primer registro mundial de tetroftalmia con sinoftalmia unilateral en condriactios.

Palabras clave: Chondrichthyes, malformaciones orbitales, siameses, captura incidental, embriogénesis

Abstract.- This study describes and classifies a case of multiple malformations in an unborn blue shark *Prionace glauca* fetus, which was extracted from a gravid female captured during a research campaign addressed to the biological study of sharks in northern and central Chile. The analyzed specimen shows tetrophthalmia with unilateral synophthalmia, anomaly characterized by the existence of 4 ocular globes, two of which are partially fused. In addition, the axial skeleton of the fetus shows thoracic lordosis and helical torsion in the abdominal-caudal portion. This is the first world report of tetrophthalmia with unilateral synophthalmia in chondrichthyans.

Key words: Chondrichthyes, orbital malformations, conjoined twins, bycatch, embryogenesis

INTRODUCTION

Although its occurrence is rare (Black *et al.* 2012), the presence of morphological abnormalities has been widely reported in humans (*e.g.*, Howard 1977, Hausmann *et al.* 1992, Jensen *et al.* 2007) and animals (*e.g.*, Maggs *et al.* 2009). In the latter, such malformations have even been experimentally induced, by genetic manipulation (Halder *et al.* 1995) as well as by the action of physical and chemical agents (Raven *et al.* 1955, Howard 1977), suggesting a multifactorial etiology. Examples of this can also be found in nature, where different orbital alterations have been associated

to causes so diverse as chromosomal anomalies (Howard 1977), phytotoxic conditions, hypovitaminosis (Maggs *et al.* 2009) and intrauterine infections (Sadler & Langman 2007).

Relatively few reports of morphological abnormalities in sharks are found in the literature, which have mainly focused in the description of bicephalous (Goto *et al.* 1981, Bejarano-Álvarez *et al.* 2011, Delpiani *et al.* 2011, Galván-Magaña *et al.* 2011, Ehemann *et al.* 2016), diprosopus (Hevia-Hormazábal *et al.* 2011) and xyphopagus twins (Ferreira *et al.* 2000)¹. Other

¹Ferreira LA, TGA Ferreira & LE Oliveira. 2000. Ocorrência de xifopagia em embrião de tubarão-azul, *Prionace glauca* (Linnaeus, 1758) (Carcharhinidae, Carcharhiniformes). In: Resumos da 2ª Reunião da Sociedade Brasileira para Estudo em Elasmobrânquios - SBEEL, p. 71

deformities include spinal cord (Mancini *et al.* 2006) and dental abnormalities (Sáez & Pequeño 2010). Albinism has also been reported in several species (*e.g.*, Teixeira & Araujo 2002).

Other morphological anomalies reported in sharks include cyclopia (Mancini *et al.* 2006, Castro 2011) and bilateral absence of eyes (Bejarano-Álvarez *et al.* 2011), called anophthalmia (Sadler & Langman 2007). These two are part of a wide array of orbital anomalies, which also comprises synophthalmia (incomplete ocular fusion), microphthalmia (presence of severely hypoplastic eyes), diplophthalmia (total duplication of one eye) (Hausmann *et al.* 1992, Sadler & Langman 2007) and development of supernumerary eyes (Raven *et al.* 1955, Jensen *et al.* 2007).

Prionace glauca (Linnaeus, 1758) is a neritic-oceanic species, circumglobal in tropical and temperate seas (Compagno 1984), and its distribution in Chile extends from Arica (18°S) to Puerto Montt (41°S). Its reproduction is placental viviparous (Galván-Magaña *et al.* 2011), with a gestational period of 9 to 12 months (Nakano & Seki 2003), after which the female gives birth to 4 to 135 offsprings per liter (Compagno 1984). The size at birth is between 35 and 44 cm total length (LT) (Sáez & Pequeño 2010), with newborn specimens showing advanced developmental stage and total independence on the mother (Compagno 1984).

Recently, several embryonic abnormalities have been reported in *Prionace glauca* (Bejarano-Álvarez *et al.* 2011, Galván-Magaña *et al.* 2011, Hevia-Hormazábal *et al.* 2011, Ehemann *et al.* 2016) and other carcharhinid species (Delpiani *et al.* 2011). In the present study, a case of tetraphthalmia with unilateral synophthalmia in a *P. glauca* fetus captured in Chilean waters is described and classified.

MATERIALS AND METHODS

Between November 2000 and August 2001, during a biological study on pelagic sharks off northern and central Chile, 33 gravid female *P. glauca* were captured and examined in the laboratory (Acuña *et al.* 2001). Inside one of them, a fetus with multiple morphological abnormalities was found, fixed with 10% formaldehyde and stored in 90% ethanol in the ichthyological collection of the Guayaacán Campus of Universidad Católica del Norte, Chile (Reference code SCBUCN - 3617). For the descriptive analysis of the specimen, external morphological, morphometric (Compagno 1984) and radiological

examinations were done. The craniofacial deformities were classified according to the criteria described by Hausmann *et al.* (1992).

RESULTS

The analyzed specimen is a female unborn fetus of 152 mm TL. Its other morphometric data is included in Table 1. Morphologically, the specimen shows 4 eyeballs: 3 laterals (Figs. 1a y b) and one submedial, localized between the middle line and the left ocular region (Fig. 1c). The right (Fig. 1b) and submedial eyeballs are simple, while the left ones are partially fused (Fig. 1a). These last ones, longitudinally joined at the iris level, are the same size (Table 1) and share a common sclera. The submedial eye, partially covered by dermic folds, is hypoplastic (Fig. 1c). Externally, the Meckel cartilage looks normal, while the palatoquadrate shows a notorious deformity (Fig. 1). Teeth, present in both mandibles, do not show morphological anomalies. The rostrum is shifted towards the left in the sagittal plane and shows a slight clockwise torsion (Fig. 1c). The spiracles are absent, but the number and relative position of fins and gill slits are normal (Table 1, Fig. 1). The pectoral and pelvic fins are slightly asymmetric (Table 1, Fig. 1), the dorsal fins are folded (Fig. 1a), and the caudal, coiled (Fig. 1). The umbilical cord is 14.8 mm long and 8.0 mm wide (Fig. 1c). The axial skeleton shows thoracic lordosis and dextrogyre helical torsion in the abdominal-caudal portion (Fig. 1). The epidermal pigmentation is normal, except for a darker sector that connects the three periocular regions (Fig. 1c).

DISCUSSION

Based on the classification criteria used, we propose the term tetraphthalmia with unilateral synophthalmia to denote the orbital malformation reported in this study. Due to the invariable association between synophthalmia and severe alterations in brain development, the described dysmorphic assemblage is incompatible with postnatal life (Hausmann *et al.* 1992, Sadler & Langman 2007).

This is the first world record of tetraphthalmia with unilateral synophthalmia in chondrichthyans, and there have been no reports of this disorder in nonchondrichthyan vertebrates. According to Hausmann *et al.* (1992), this malformation would be

Table 1. Morphometric characterization (mm) of the tetrophthalmic blue shark fetus caught in Chilean waters / Caracterización morfológica (mm) del feto de tiburón azul tetroftálmico capturado en aguas chilenas

Morphometric characteristics	Size	Right	Sub-medial	Left	Morphometric characteristics	Size	Right	Sub-medial	Left
Total length	152.0				Pelvic-fin length		20.2		17.2
Precaudal length	144.4				Pelvic-fin base		12.3		9.4
Predorsal length	113.4				Pelvic-fin height		11.3		7.1
Cephalic length	86.9				Pelvic-fin anterior margin		19.1		15.8
Cephalic height	31.8				Pelvic-fin posterior margin		14.3		8.2
Cephalic width	44.2				First dorsal-fin length	33.2			
Prebranchial length		75.6		78.0	First dorsal-fin base	25.4			
Preorbital length		34.2	36.6	36.9	First dorsal-fin height	17.7			
Prenarial length		22.2		24.8	First dorsal-fin anterior margin	30.1			
Preoral length	50.3				First dorsal-fin posterior margin	25.4			
Prepectoral length		85.5		86.8	Second dorsal-fin length	22.3			
Preumbilical length	77.8				Second dorsal-fin base	17.5			
Prepelvic length		107.8		117.0	Second dorsal-fin height	6.9			
Preanal length	112.2				Second dorsal-fin anterior margin	14.4			
Eye length		19.5	12.9	11.1	Second dorsal-fin posterior margin	16.8			
Eye height		11.4	9.2	14.4	Anal-fin length	21.3			
Mouth length	12.8				Anal-fin base	11.2			
Mouth width	26.2				Anal-fin height	7.7			
Nostril width		5.3		5.4	Anal-fin anterior margin	14.4			
Interorbital space		9.4		12.0	Anal-fin posterior margin	9.4			
Internarial space	10.1				Trunk height	41.1			
Intergill length		10.0		14.6	Trunk width	38.0			
First gill slit height		12.7		11.1	Umbilical cord length	14.8			
Second gill slit height		13.4		8.6	Umbilical cord maximum (subdistal) width	8.0			
Third gill slit height		13.6		9.7					
Fourth gill slit height		13.3		10.3					
Fifth gill slit height		11.4		9.0					

consecutive to twin fusion, being in the same pathological context of bicephalic and diprosopic twins (Fig. 2).

The optic primordia are formed from the neural plate, after the division of the ocular field (Li *et al.* 1997). This process, similar in all vertebrates (Cagan & Reh 2010), is regulated by a polygenic system, which correct performance is key for the existence of bilateral eyes (Varga *et al.* 1999, Sadler & Langman 2007). From this perspective, the presence of 4 eyes in the analyzed specimen is attributable to the preexistence of two ocular fields, one of which (the one from the left twin) did not separated, causing unilateral synophthalmia.

Malformations in sharks have been attributed to several causes, among them genetic anomalies, parasitosis, malnutrition, arthritis, mechanical injuries, presence of tumors and pollution (Mancini *et al.* 2006, Delpiani *et al.* 2011). However, these causes should not be considered for *P. glauca* because of the highly migratory lifestyle of this species (Acuña *et al.* 2001). Another cause, of special importance in *P. glauca*, could be polyembryony (Mancini *et al.* 2006), since this species produce large litters, up to 135 offsprings, being the most fecund species of the group (Compagno 1984). Thus, the intrauterine area of *P. glauca* could be small to bear a high number of offsprings, with the consequent risk of placental insufficiency. Due to this

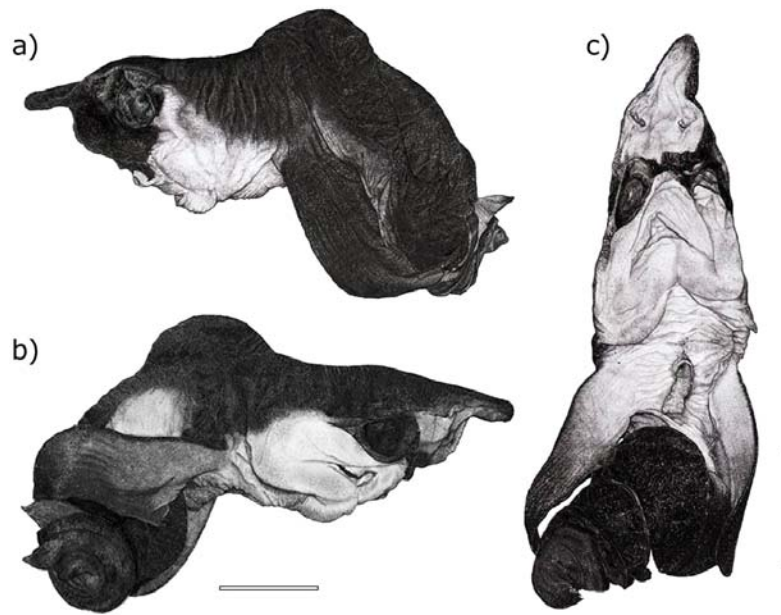


Figure 1. Blue shark fetus affected by tetrophthalmia with unilateral synophthalmia caught in Chilean waters. a) Left lateral view, b) right lateral view and c) ventral view. Scale bar: 30 mm / Feto de tiburón azul afectado por tetroftalmia con sinoftalmia unilateral capturado en aguas chilenas. Vista lateral derecha (a), lateral izquierda (b) y ventral (c). Barra escalar: 30 mm

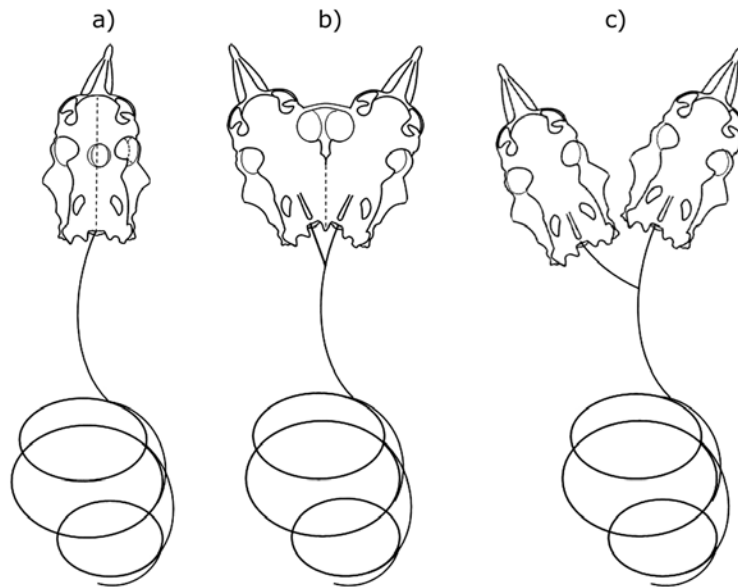


Figure 2. Comparative scheme of 3 blue shark specimens with congenital malformations: (a) tetrophthalmic fetus described in the present study; (b) diprosopus twins reported by Hevia-Hormazábal *et al.* (2011); (c) bicephalous twins presented by Goto *et al.* (1981) / Esquema comparativo de 3 especímenes de tiburón azul con malformaciones congénitas: (a) feto tetroftálmico descrito en el presente estudio; (b) gemelos diprósopos reportados por Hevia-Hormazábal *et al.* (2011); (c) gemelos bicéfalos presentados por Goto *et al.* (1981)

fact, nutrient transfer to the fetus could be limited, producing deleterious effects over their development and growth, which is evident if abnormal fetuses are compared with normal ones of similar age (*e.g.*, Hevia-Hormazábal *et al.* 2011).

Orbital malformations have generally low prevalence in vertebrates (Black *et al.* 2012), being particularly rare in chondrichthyan fish, where only two cases of cyclopia (Mancini *et al.* 2006, Castro 2011, Bejarano-Álvarez & Galván-Magaña 2013) and one of anophthalmia (Bejarano-Álvarez *et al.* 2011) have been reported, all of which correspond to *P. glauca*.

Given this lack of records, the analysis of commercially captured sharks could constitute an effective alternative to improve the knowledge of the etiology and epidemiology of these deformities. However, initiatives such as this could be faced with different logistical difficulties. This partially occurs in the chondrichthyan fisheries in Chile, where *P. glauca* is not a target species, but is mainly part of the bycatch of the artisanal and industrial fleets that target other species, such as *Isurus oxyrinchus* and *Xiphias gladius*, respectively (Acuña *et al.* 2001). The artisanal longline fishery that targets *I. oxyrinchus* operates primarily seasonally (spring-summer) in the coastal zone off northern Chile and normally does not have access to adult specimens. By contrast, in the industrial longline fishery that targets *X. gladius*, most of the *P. glauca* specimens used to be discarded, and only their fins are retained, making it difficult to have access to samples of this species (Acuña *et al.* 2002). However, in this last case, Chile passed during 2011 a law against finning, and now the whole bodies of the sharks caught must be landed, making it possible to have access to *P. glauca* female specimens.

ACKNOWLEDGMENTS

We are grateful to D. Céspedes, N. Piaget and G. Díaz for valuable advice and collaboration during the process of this study. This contribution was supported by Department of Marine Biology of Universidad Católica del Norte and Fondo de Investigación Pesquera (FIP) - Project N° 2000-23. JMA Vega acknowledges the support of BECA CONICYT and Programa de Doctorado en Biología y Ecología Aplicada (<www.bea.cl>).

LITERATURE CITED

- Acuña E, L Cid, E Pérez, I Kong, M Araya, J Lamilla & J Peñailillo. 2001. Estudio biológico de tiburones (marrajo dentado, azulejo y tiburón sardinero) en la zona norte y central de Chile. Informes Técnicos FIP, FIP/IT N° 2000-23: 1-112. <http://www.subpesca.cl/fipa/613/articulos-88952_informe_final.pdf>
- Acuña E, JC Villarroel & R Grau. 2002. Fauna íctica asociada a la pesquería de pez espada (*Xiphias gladius* Linnaeus). *Gayana* 66: 263-267.
- Bejarano-Álvarez OM & F Galván-Magaña. 2013. First report of an embryonic dusky shark (*Carcharhinus obscurus*) with cyclopia and other abnormalities. *Marine Biodiversity Records* 6(11): 1755-2672.
- Bejarano-Álvarez OM, F Galván-Magaña & RI Ochoa-Báez. 2011. Further observations on foetal abnormalities in the blue shark *Prionace glauca* (Chondrichthyes: Carcharhinidae) from north-west Mexico. *Marine Biodiversity Records* 4: e82. <<https://doi.org/10.1017/S1755267211000790>>
- Black EH, FA Nesi, CJ Calvano, GJ Gladstone & MR Levine. 2012. *Smith and Nesi's ophthalmic plastic and reconstructive surgery*, 1330 pp. Springer-Verlag, New York.
- Cagan RL & TA Reh. 2010. *Invertebrate and vertebrate eye development*, 312 pp. Elsevier, San Diego.
- Castro JI. 2011. *The sharks of North America*, 612 pp. Oxford University Press, New York.
- Compagno LJV. 1984. *FAO Species Catalogue. Vol.4. Sharks of the world, an annotated and illustrated catalogue of shark species known to date. Part 2. Carcharhiniformes*. *FAO Fisheries Synopsis* 125 4(2): 251-655.
- Delpiani SM, MY Deli Antoni, SA Barbini & DE Figueroa. 2011. First record of a dicephalic specimen of tope *Galeorhinus galeus* (Elasmobranchii: Triakidae). *Journal of Fish Biology* 78(3): 941-944.
- Ehemann N, J Marín-Sanz & M Barany-González. 2016. Two cases of two-head shark embryos, smalleye smoothhound *Mustelus higmani* and blue shark *Prionace glauca*. *Boletín de Investigaciones Marinas y Costeras* 45(1): 149-153.
- Galván-Magaña F, O Escobar-Sánchez & M Carrera-Fernández. 2011. Embryonic bicephaly in the blue shark, *Prionace glauca*, from the Mexican Pacific Ocean. *Marine Biodiversity Records* 4: e1. <[doi:https://doi.org/10.1017/S1755267210001120](https://doi.org/10.1017/S1755267210001120)>.
- Goto M, T Taninuchi, N Kuga & M Iwata. 1981. Four dicephalous specimens of blue shark, *Prionace glauca*, from Japan. *Japanese Journal of Ichthyology* 28(2): 157-165.
- Halder G, P Callaerts & WJ Gehring. 1995. Induction of ectopic eyes by targeted expression of the eyeless gene in *Drosophila*. *Science* 267: 1788-1792.

- Hausmann N, FH Stefani & EO Lund. 1992.** Diplophthalmia versus cyclopia and synophthalmia. Mechanisms of doubling of the eye. *Documenta Ophthalmologica* 79(3): 201-219.
- Hevia-Hormazábal V, V Pastén-Marambio & A Vega. 2011.** Registro de un monstruo diprósopo de Tiburón azul (*Prionace glauca*) en Chile. *International Journal of Morphology* 29(2): 509-513.
- Howard RO. 1977.** Chromosomal abnormalities associated with cyclopia and synophthalmia. *Transactions of the American Ophthalmological Society* 75: 505-538.
- Jensen H, SA Pedersen, OA Jensen, M Hering & M Warburg. 2007.** Unilateral ocular duplication. *Ophthalmic Genetics* 28(2): 83-88.
- Li H, C Tierney, L Wen, JY Wu & Y Rao. 1997.** A single morphogenetic field gives rise to two retina primordial under the influence of the prechordal plate. *Development* 124(3): 603-615.
- Maggs DJ, PE Miller & R Ofri. 2009.** *Fundamentos de oftalmología veterinaria*, 504 pp. Elsevier, Madrid.
- Mancini PL, AL Casas & AF Amorim. 2006.** Morphological abnormalities in a blue shark *Prionace glauca* (Chondrichthyes: Carcharhinidae) foetus from southern Brazil. *Brazilian Archives of Biology and Technology* 69(6): 1881-1884.
- Nakano H & M Seki. 2003.** Synopsis of biological data on the blue shark, *Prionace glauca* Linnaeus. *Bulletin of the Fisheries Research Agency* 6: 18-55.
- Raven P, AC De Room & AM Stadhouders. 1955.** Morphogenetic effects of a heat shock on the eggs of *Limnaea stagnalis*. *Journal of Embryology and Experimental Morphology* 3(2): 142-159.
- Sadler TW & J Langman. 2007.** *Embriología médica con orientación clínica*, 386 pp. Editorial Médica Panamericana, Buenos Aires.
- Sáez S & G Pequeño. 2010.** Claves para el reconocimiento taxonómico dentario en taxa del Superorden Squalomorphi de Chile (Chondrichthyes: Elasmobranchii). *Latin American Journal of Aquatic Research* 38(2): 474-484.
- Teixeira SF & MG Araujo. 2002.** First record of albinism in the smooth dogfish *Mustelus schimitti* from Southern Brazil. *Brazilian Archives of Biology and Technology* 45(2): 241-243.
- Varga ZM, J Wegner & M Westerfield. 1999.** Anterior movement of ventral diencephalic precursors separates the primordial eye field in the neural plate and requires cyclops. *Development* 126(24): 5533-5546.

Received 14 October 2016 and accepted 07 July 2017

Editor: Claudia Bustos D.